

Study of 70 degree endoscopy in opd patients with throat complaints attending newly establish GMC Rajouri and AH

Dr. POOJA GADGOTRA

Medical officer, District Hospital Reasi, J&K

Dr. MUKHTAR KHAN¹

Assistant professor

Department of ENT, Government Medical College, Rajouri, J&K

Dr. VIJAY GUPTA

Ex-Professor

Department of ENT, Government Medical College, Rajouri, J&K

Abstract:

Background: Endoscopy has currently been an indispensable method in many areas of otorhinolaryngology. Rigid telescopes are widely used in otorhinolaryngology for endolaryngeal visualization. Laryngeal telescopes are made with several angles, like 70 and 90-degree. In our study, a 70-degree rigid endoscope was used for examining larynx.

Material and Method: The study was conducted on 65 patients over a period of one year from October 2020 to September 2021. We used 70 degree endoscope in attempt to visualize larynx. Endoscope were connected to a video camera through fibre-optic cable and videotape recording were made.

Result: Commonest age group affected was 41-50 years (33%), 31-40 years (15.38%), 21-30 years (15.38%), 61-70 years (12.30%), 51-60 years (10.76%), 11-20 years (4.6%) and 71-80 years (3%). Male (60%) predominance as compared to females (40%). Voice change was the most common symptom followed by heart burn, acidity, throat pain (27.69%), foreign body sensation (18.46%), suspected foreign body (9.2%), neck mass (4.6%), difficulty in breathing and neck trauma (1.5%). Most common provisional diagnosis is GERD (24.6%) followed by acute non specific laryngitis (19.2%), laryngeal mass (12.3%), vocal cord polyp, negative findings each (7.6%), dysphagia under evaluation (6.1%), vocal cord paralysis (3%), reinkes odema (1.5%) and granuloma a (1.5%). Only 10 % of patients need local anesthesia. Procedure was successful in 95%. No complication was reported.

Conclusion: In the present study, 95% of the cases 70 degree examination was adequate to aid in diagnosis of laryngeal pathology.

Keywords: Larynx, Laryngeal lesion, Rigid endoscopy.

INTRODUCTION

Garcia was credited with first description of mirror indirect laryngoscopy [9]. Bozzinni was actually the first to report on mirror visualization of the larynx and described the first indirect laryngoscope [5].

In 1909 Killian introduced the suspension laryngoscopy and Kleinsasser in 1960 developed monocular telescope and discovered the great possibilities of this

¹ Corresponding Author

magnification in detecting early pathological changes [20]. Later Scalo described the use of Zeiss operating microscope with suspension laryngoscopy [11].

Hopkin rods greatly increased the magnification and depth for detailed observation during examination of the larynx; also they were modified to view in different examination [17].

The invention of Hopkin rod telescope and flexible endoscope reserved direct laryngoscopy for therapeutic intentions. Laryngeal disorders are multifactorial in origin and to complicate matters patient may develop compensatory vocal behaviours in order to communicate effectively which may mask the true underlying or primary disorder [21].

Visual inspection of the larynx is important for the diagnosis or exclusion of laryngeal disease.

The method of laryngeal examination varies from indirect mirror laryngoscopy to the use of rigid and flexible endoscopes [16].

The larynx is a complex organ, and it is anatomically comprised of several folds, elastic membranes, ligaments and muscles constructed on a cartilaginous framework .

These structures can be involved in several disorders, and some of the regions can be quite challenging for assessment with conventional methods [8].

Previously indirect laryngoscopy is the basic method to examine the larynx. Direct laryngoscopy with biopsy is the traditional way to delineate the lesion and have histological diagnosis. With progress in technology, opd examination has evolved, including rigid endoscopy (70,90) fibroscopy and stroboscopy with video recordings [7,12]. There are certain regions of larynx such as anterior commissure, ventricles and subglottic areas which are still difficult to visualize. For this purpose rigid endoscopes have been introduced and 0, 30, 70, 120 degree telescopes are available for the assessment of these difficult areas during microlaryngeal examination under general anesthesia [8].

MATERIAL AND METHOD

A total of 65 patients attending the department of ENT, GMC Rajouri and AH were included for this study. Patients of both sexes were included. This prospective study was carried from October 2020 to September 2021.

Inclusion criteria

Patients with complaints related to larynx and upper aerodigestive tract like change in voice, throat pain, neck swelling, difficulty in swallowing were included in the study.

Exclusion criteria

Patient with difficulty in breathing, acute respiratory distress, with cervical spine pathology, trismus or allergic to local anesthesia.

The number of patients who fulfilled the above criteria and qualified for the study were 65 patients.

Full clinical assessment was done for all patients. Special attention was taken regarding change in voice, pain on vocalization, difficulty in swallowing, foreign body sensation in throat, history of trauma, neck mass, foreign body ingestion, heart burn, acidity and past history of any surgery or endotracheal intubation.

Equipment used for rigid videolaryngoscopy: All patients underwent videolaryngoscopy using 70 degree, 4mm rigid endoscope.

Technique for laryngoscopy using 70-degree 4mm endoscope:

Patient was made to sit on a chair. Usually no topical anesthesia was required; however 10% xylocaine spray was applied to the base of tongue and the posterior pharyngeal wall if there is over sensitive gag reflex. The doctor stands in front of the patient while he was bending slightly forward with slight extension of the head. The tongue of the patient is pulled out with left hand using a piece of gauze and with his right hand the scope lens was facing down and introduced forward through the oral cavity avoid touching the tongue. In case of any difficulty to examine anterior commissure area of the larynx, extension of the head was increased, the endoscope handle was further elevated to make its shaft touches the upper incisors and the tip of the scope is slightly further advanced to aid viewing these area. To evaluate all parts of the larynx, the scope was half rotated to the sides. Video movies were recorded for every patient. Picture of the findings can be done when needed.

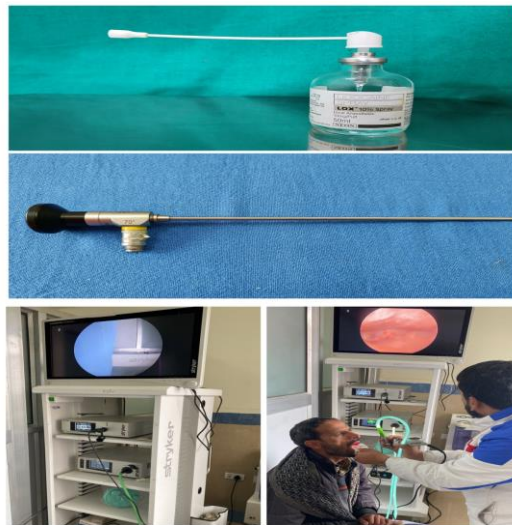

Fig 1: Picture showing different instruments, position, procedure and local anesthesia used

RESULTS

Rigid videolaryngoscopy by endoscope was successful in 62/65 patients (95%). The commonest age group affected by laryngeal disease was 41-50 years. 39 were males (60%) and 26 patients were females (40%) with male:female ratio is 1.5:1.

Table no.1: Sex distribution of patients.

Sex distribution	No. of patients
Male	39 (60%)
Female	26 (40%)
Total	65

Table.2: Age distribution of patients.

Age group of patients	No. of patients
0-10	-
11-20	3 (4.6%)
21-30	10(15.38%)
31-40	13 (20%)
41-50	22 (33.84%)
51-60	7 (10.76%)
61-70	8 (12.30%)
71-80	2 (3.0%)
Total	65

Table.3: Frequency of symptoms in patients.

Symptoms of patient	No. of patients
Voice changes	36 (55.38%)
Neck mass	3 (4.6%)
Throat pain	18 (27.69%)
Difficulty in swallowing	4 (6.1%)
Forigen body sensation	12 (18.46%)
Suspected forigen body	6 (9.2%)
Difficulty in breathing	1 (1.5%)
Heart burn and acidity	18 (27.69%)
Neck trauma	1 (1.5%)

Table.4: Provisional diagnosis of patients with symptoms.

Provisional diagnosis	No. of
Negative findings	5(7.6%)
Acute non-specific laryngitis	6 (19.2%)
Chronic non-specific Laryngitis	3 (4.6%)
Chronic pharyngitis	8 (12.3%)
Vocal cord paralysis	2 (3%)
Dysphagia underevaluation	4 (6.1%)
Vocal cord polyp	5 (7.6%)
Vocal cord nodule	3 (4.6%)
Laryngeal mass	8 (12.30%)
Reinkes odema	1(1.5%)
GERD,LPR	16(24.6%)
Forigen body	3 (4.6%)
Subglottic stenosis	1 (1.5%)

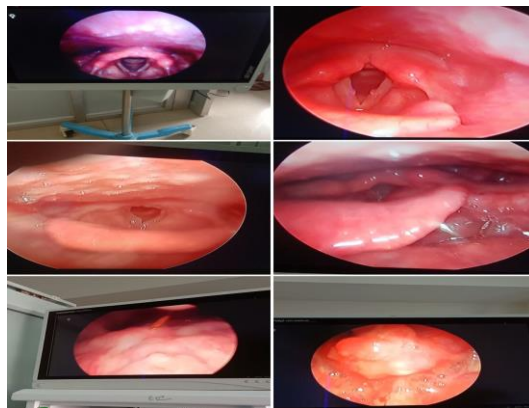


Fig 2: Picture showing 70 degree endoscopic view with different pathologies (vocal nodule, vocal polyp, forigen body, mass).

Table.5: Anesthesia used in patients.

Local anesthesia	No. of patients
Not used	58 (89.23%)
Used	7 (10.76%)
Total	65

Table.6: Successfulness of procedure in patients.

Successfulness	No. of patients
Successful	62 (95.38%)
Failure	3 (4.6%)
Total	65

Table.7: Complications of procedure in patients.

Complications	No. of patients
Yes	-
No	65 (100%)
Total	65

DISCUSSION

Commercially, four types of rigid endoscopes (0, 30, 70, 120) are available for visualization of larynx. Each may have its own advantage, but the 70-degree endoscope is most often proposed for the visualization of the obscured areas of the larynx, anterior commissure, ventricles and subglottic region [3]. Considering the economic burden of having four types of endoscopes at the same time, we used only 70 degree endoscope in our study.

Rigid videolaryngoscopy by 70 degree endoscope was successful in 62 patients (95.38%) which resemble study of Ehab [23]. 70 degree endoscope is able to approach the vocal fold more closely. This closer physical approach may explain the better visualization of the laryngeal surface of the epiglottis, the anterior commissure, and the subglottic area by the 70 degree [22].

In study of Kishore, 70 degree endoscopy in critical zones, anterior commissure visualized in 95%, ventricles 90% and subglottis 90% of cases [14].

Eryilmaz et al stated that 70 degree endoscopy superior with 70-100% sensitivity [8].

Literature search revealed only handful of articles published which were in line with our study.

In our study, 39 patients were males (60%) and 26 were females (40%) with 1.5 :1 as male to female ratio.

In study of Ehab, 42 patients were males (62.7%) and 25 were females (37.3%) with 1.68:1 as male to female ratio which resembles our study [23].

In study by Kaushik, 45 (56.30%) were males, 35 (43.80%) were females and male female ratio of 1.28:1. which resembles our study [13].

In a study by Kishore et al, male corresponds to 70 % and females are 30% . Male to female ratio is 2.3 [14].

Male to female ratio in Baitha et al, Mehta, Parikh, Deshmukh with 2:1, 1.8:1, 2:1 and 1.5:1 respectively [4,15,19,6] .

In our study, the commonest age group affected by laryngeal diseases was 41-50 yrs (33.84%) which resemble study of Ehab who also reported same age group as most commonly affected [23].

In study of Kishore et al, majority of patients fell in age group 51-60 years which is different from our study [14].

In study by Kaushik, majority of patients fall in 51-60 years of age group which is different from our study [13].

Herrington-Hell et al stated that taking the variable of age into account, laryngeal pathologies occur most frequently in older age group because carcinoma and vocal fold paralysis being most common cause of vocal dysfunction in the elderly [10].

In our study, change in voice is the most common chief complaint in 36 patients (55.38%) which resembles study of Kishore et al who also reported hoarseness of voice as the commonest presenting complaint in 53% [14].

In literature available to us, incidence of hoarseness among patients attending ENT OPD couldnot be found. This problem has been encountered by some other wokers like Mehta who has mentioned that a search of available literature on laryngology for the comparative incidence of cause of hoarseness of voice was unfruitful [15]. Parikh also comments – “ Its strange that hoarseness as a subject has not attracted the attention of many workers” [19].

In study by Ehab, neck mass in 6 patients (9%), difficulty in swallowing in 6 patients (9%) and forigen body sensation in 8 patients (12%) which resembles to our study where neck mass in 3 patients (4.6%), difficulty in swallowing in 4 patients (6.1%) and forigen body sensation in 12 patients (18.46%) [23].

In Kishore et al study, throat pain in 41%, difficulty in breathing in 3%, burning sensation of throat in 24%, throat pain in 36.9% ,difficulty in breathing in 1.5% and burning sensation of throat in 27.69% [14].

In our study, acute non-specific laryngitis is seen in 5 patients (7.6%)

In our study, chronic non-specific laryngitis is seen in 3 patients (4.6%) which resembles study of ehab where it is 4.5 % (3 patients) [23].

In our study, dysphagia under evaluation is present in 4 patients (6.1%) which resembles study of kishore where it is 8% [14].

In our study, 2 patients (3%) had left vocal cord paralysis with equal sex incidence which resemble study of Ehab where 4 patients (6%) are reported with left cord paralysis [23]. Perry said that left vocal cord paralysis is 10 times more common than right vocal cord paralysis [21].

In our study, vocal polyps are seen in 5 patients (7.6%) which resembles study of kishore and ehab where it is 4% and 9% (6 patients) [14].

In our study, vocal cord nodule were seen in 4 patients (6.1%) which is 11% and 13.4% in kishore and ehab study which is nearly resembling our study [14,23].

In our study, laryngeal mass is seen in 8 patients (12.3%) which is nearly resembling study of kishore where it is 18% [14].

Reinkes odema is seen in 1 patient (1.5%) which is in line with kishore (1%)and Ehab (4.5%) study [14].

In our study, GERD is reported in 16 patients (24.61%) which resembles study of Kishore where it is 28%[14].

In our study, 3 patients (4.61%) had forigen body. Out of 3 patients , 2 had fish bone and one female with steel utensil scrubber.

Study of Ehab reported 2 cases (3%) of forigen body which resemble our study [23].

In our study, one patient had subglottic stenosis who was intubated for 5-6 days after head injury which resembles study of Ahn and Abbasi where most of tracheal stenosis experienced up to 5 days of intubation [1,2,].

In our study, only 7 patients (10.76%) need application of 10% lignocaine rest 89% donot need any type of anesthesia.

In study of Ehab, 4 patients (6%) need local anesthesia which resembles our study [23].

It is a procedure free of complications except for gagging and failure to visualize the lesion.

In our study, there is no complication.

In study of Ehab, no complications reported which resembles our study [23].

In Shao J study, no complications arose from the evaluation with 70 degree telescopes. 2 patients were discontinued due to patients hyperactive gag reflexs [22].

CONCLUSION

In this study, we attempt to demonstrate the use of 70 degree videolaryngoscopy in our opd setup. Our study concludes that 70 degree endoscope were successful in 95% of patients and only 10% need local anesthesia. Though , learning the technique requires effort, but definitely can be mastered with practice. We believe that this technique may form the basis for early diagnosis of laryngeal lesion which lead to early access of health care facility and seeking early treatment. Rigid laryngoscopy provides a better, clear magnified view of the larynx

BIBLIOGRAPHY

1. Abbasi AE, Saeidi F, Behgam SM, Arab M, Amjadi MR, Pirmouazen NAD, et al. Surgical treatment for upper airway stenosis secondary to tracheal intubation. *J Med Council I.R.I* 2000;18(3):185-91.
2. Ahn HY, Su cho J, Kim YD, I H. Surgical outcomes of post intubational or post tracheostomy tracheal stenosis: reort of 18 cases in single institution. *Ann Thorac Cardiovasc Surg.* 2015;21(1):14-7
3. Andrea M, Dias O, Newer techniques of laryngeal assessment. In: Cummings CW Otolaryngology Head Neck Surgery, 3rd edition. Mosby, St Louis, pp 1967-1978.
4. Baitha S, Raizada RM, Kennedy Singh AK, Puttewar MP, Chaturvedi VN. Clinical profile of hoarseness of voice. *Indian J Otolaryngol Head Neck Surg.* 2002;54(1):14-8.
5. Bozzinni P. Der Lichtleiter oder Beschreibung einer einfachen Vorrichtung, und ihrer Anwendung zur erleucht ung inhere Hohlen, und Zwischenraume des lebenden animaschen Körpers. Weimar, 1807.
6. Deshmukh. Clinical study of hoarseness of voice. A thesis submitted for master of surgery (Otorhinolaryngology), Gujrat University, 1985.
7. Dinardo LJ, Kaylie DM, Isaacson J. Current treatment practices for early laryngeal carcinoma. *Otolaryngol Head Neck Surg* 112;519-521.
8. Eryilmaz A, Akmansu H, Topcu E. The role of 70-degree telescopic evaluation during direct laryngoscopic evaluation of laryngeal cancers. *Eur Arch Otorhinolaryngol* (2004) 261:267-269.
9. Garcia M. Observation on human voice. *Proceedings of the Royal Society of London.* 1855; 7:397-410.
10. Herrington-Hall BL, Lee L, Stemple JC, Niemi KR, MC Hone MM. Description of laryngeal pathologies by age, sex and occupation in a treatment seeking sample. *J speech Hear Disord.* 1988;53:57-64.
11. Jako G. J. Laryngoscopy for microscopic observation, Surgery and Photography. *Archives of Otolaryngology* 1970 February; 91: 196-9.
12. Kantor EA, Berci G, Partlow E, Paz-Partlow M (1991). Ancillary instruments for the video microlaryngoscope. *Ann otolrhinol laryngol* 100:317-319.
13. Kaushik MR, Kole AS, Gupta N, Dhoot S, Dehadaray A. Evaluation of various laryngeal pathologies: Videolaryngoscopy Versus Videolaryngostroboscopy. *Indian J Otol head neck surg.* 2018 Jun;70(2):244-248.
14. Kishore HR et al. *Int J Otol head and neck surg.* 2020 june;6(6):1125-1131.
15. Mehta AS. An etiological study of hoarseness of voice. A thesis submitted for master of surgery, Gujrat University, 1985.
16. McGlashan J. Disorders of voice. In: Michael Gleeson, George G browning, Martin J Burton et al. editors. *Scott-Browns Otorhinolaryngology, Head and Neck Surgery* 7th Edn. London: Hodder Arold; 2008. P. 2192-210.
17. Now J. B.,Wackym P.A. Laryngoscopy. *Ballengers Otorhinolaryngology, head neck surgery.* Seventeenth Edition, BC Decker Inc. 2009, 83: 955-62.

18. Parab SR, Khan M. Does the angle of rigid endoscope makes a difference in videolaryngoscopy. Ind J Otol Head and neck surg. 2019 oct; 71(suppl 1):605-609.
19. Parikh N. Aetiology study of 100 cases of hoarseness of voice. Indian J Otolaryngol head neck surg. 1991;43(2):71-3.
20. Pashcow M. S., Mattuci K. F. Direct Laryngoscopy; retrospective analysis. International Surgery 1978; October-December; 68(4): 331-5.
21. Perry A. Speech therapy in ENT practice: scope, science and evidence for intervention. In: Michael Gleeson, George G browning, Martin J Burton et al. editors. Scott-Browns Otorhinolaryngology Head and Neck Surgery 7th Edn. London: Hodder Arnold;2008. P. 2216-33.
22. Shao J, Stern J, Wang MZ. Clinical evaluation of 70 degree and 90 degree laryngeal telescopes. Arch otolaryngol head and Neck surg. 2002;128:941-944.
23. Yaseen ET. Videolaryngoscopy by using 70 – degree 4mm rigid sinuscope in comparison with flexible fiberoptic laryngoscopy. Iraqi journal of community medicine. 2012,vol 25(4)357-362.